SCUOLA DERMATOLOGICA
SERGIO CHIMENTI

NOVITÀ IN DERMOSCOPIA DELLE LESIONI PIGMENTATE

Alessandro Di Stefani

Istituto di Dermatologia
Fondazione Policlinico Universitario A. Gemelli
Università Cattolica del Sacro Cuore, Roma

Presidente AIDNID
ASSOCIAZIONE ITALIANA DI DIAGNOSTICA NON INVASIVA IN DERMATOLOGIA
www.aidnid.org

AIDNID

AJCC Cancer Staging Manual
8TH Edition



© 2017

AJCC Cancer Staging Manual

Editors: **Amin**, M.B., **Edge**, S., **Greene**, F., **Byrd**, D.R., **Brookland**, R.K., **Washington**, M.K., **Gershenwald**, J.E., **Compton**, C.C., **Hess**, K.R., **Sullivan**, D.C., **Jessup**, J.M., **Brierley**, J.D., **Gaspar**, L.E., **Schilsky**, R.L., **Balch**, C.M., **Winchester**, D.P., **Asare**, E.A., **Madera**, M., **Gress**, D.M., **Meyer**, L.R. (Eds.)

Springer

The AJCC Cancer Staging Manual is the gold standard to help the cancer patient management team determine the correct stage for patients, allowing for the most appropriate care plan.

AJCC Cancer Staging Manual 8TH Edition

AJCC 8th Edition Staging

Overview

Donna M. Gress, RHIT, CTR
Technical Editor, AJCC Cancer Staging Manual
First Author, Chapter 1: Cancer Staging Principles

AJCC
American Joint Committee on Cancer
Validating science. Improving patient care.



AJCC Cancer Staging Manual 8TH Edition

AJCC Cancer Staging Manual editions

Edition	Publication	Effective dates for cancer diagnoses
1st	1977	1978 - 1983
2nd	1983	1984 - 1988
3rd	1988	1989 - 1992
4th	1992	1993 - 1997
5th	1997	1998 - 2002
6th	2002	2003 - 2009
7th	2009	2010 - 2016
8th	2016	2017 -

 Copyright © 2016 AJCC All Rights Reserved

American Joint Committee on Cancer

Melanoma of the Skin Staging

7th EDITION

Definitions

Primary Tumor (T)

- **TX** Primary tumor cannot be assessed (for example, curettaged or severely regressed melanoma)
- **T0** No evidence of primary tumor
- **Tis** Melanoma in situ
- **T1** Melanomas 1.0 mm or less in thickness
- **T2** Melanomas 1.01–2.0 mm
- **T3** Melanomas 2.01–4.0 mm
- **T4** Melanomas more than 4.0 mm

NOTE: a and b subcategories of T are assigned based on ulceration and number of mitoses per mm^2, as shown below:

T CLASSIFICATION	THICKNESS (mm)	ULCERATION STATUS/MITOSES
T1	≤1.0	a: w/o ulceration and mitosis <1/mm^2 b: with ulceration or mitoses ≥1/mm^2
T2	1.01–2.0	a: w/o ulceration b: with ulceration
T3	2.01–4.0	a: w/o ulceration b: with ulceration
T4	>4.0	a: w/o ulceration b: with ulceration

AJCC Cancer Staging Manual 8TH Edition

Skin

- Merkel cell carcinoma
  - Rule changes for cN category
  - Critical to indicate sentinel nodes only
  - Different stage groups for clinical and pathological
- Melanoma
  - New size cut points for T category
  - Mitotic rate no longer used
  - Redesigned stage tables
  - Different stage groups for clinical and pathological

 Copyright © 2017 AJCC All Rights Reserved

TNM Classification of MALIGNANT TUMOURS 8TH Edition

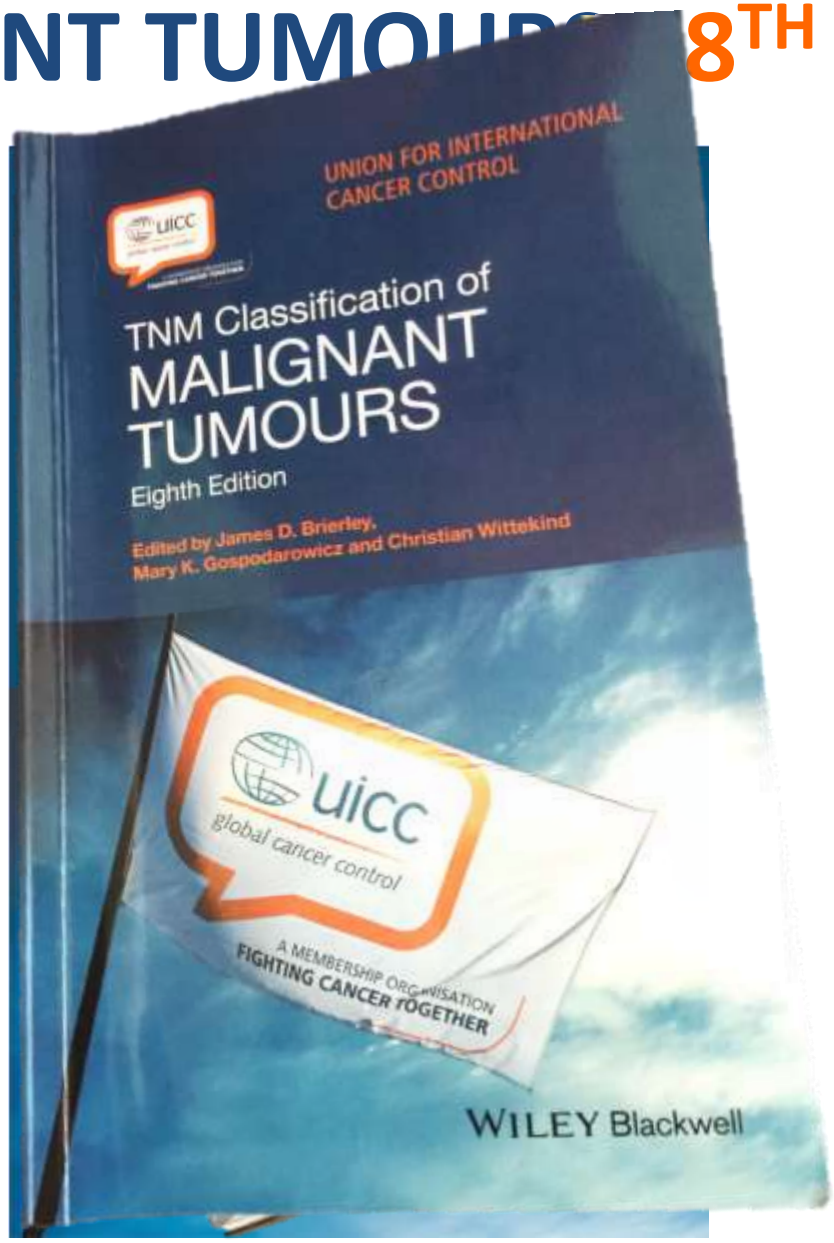

pTNM Melanoma (AJCC 8th 2017)

- p**T1**: Tumor 1mm or less in thickness
  - p**T1a**: 0.8mm or less without ulceration
  - p**T1b**: 0.8mm with ulceration
    0.8 - 1mm with or without ulceration

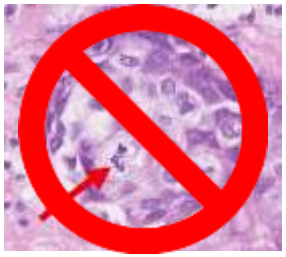

Presence of Mitoses (>1/mm^2) is no longer used!!!

NCBI Resources How To Sign in to NCBI

PubMed.gov

PubMed dermoscopy Search

Create RSS Create alert Advanced Help

Article types
Clinical Trial
Review
Customize ...

Text availability
Abstract
Free full text
Full text

PubMed Commons
Reader comments
Trending articles

Publication dates
5 years
10 years
Custom range...

Species
Humans
Other Animals

Clear all

Show additional filters

Format: Summary Sort by: Most Recent Send to Filters: Manage Filters

Search Tip
Sort by **Best Match** to display results from highest to lowest relevance to your search terms.
Try it Now

Search results

Items: 1 to 20 of 3742

<< First < Prev Page 1 of 188 Next > Last >>

1. Dermoscopic features of nail psoriasis treated with biologics.
Hashimoto Y, Uyama M, Takada Y, Yoshida K, Ishiko A.
J Dermatol. 2017 Feb 2. doi: 10.1111/1346-8138.13752. [Epub ahead of print]
PMID: 28150348
Similar articles

2. A case report of disappearing pigmented skin lesions associated with pembrolizumab treatment for metastatic melanoma.
Wolner ZJ, Marghoob AA, Pulitzer MP, Postow MA, Marchetti MA.
Br J Dermatol. 2017 Jan 28. doi: 10.1111/bjd.15354. [Epub ahead of print]
PMID: 28132411
Similar articles

3. Dermoscopic Findings in Patients with Pigmented Purpuric Dermatoses.
Çakmak SK, Kiliç A, Yorulmaz A, Onan D, Yayla D, Artüz F.
Acta Dermatovenerol Croat. 2016 Dec;24(4):291-295.

5. Update on **dermoscopy** of Spitz/Reed naevi and management guidelines by the International **Dermoscopy** Society.
Lallas A, Apalla Z, Ioannides D, Lazaridou E, Kyrgidi A, Broganelli P, Alfano R, Zalaudek I, Argenziano G; International **Dermoscopy** Society.
Br J Dermatol. 2017 Jan 24. doi: 10.1111/bjd.15339. [Epub ahead of print] Review.
PMID: 28118479
Similar articles

6. **Dermoscopy** of Papular Epidermal Nevus with Skyline Basal Cell Layer.
Balestri R, Rizzoli L, Rech G, Girardelli CR.
Pediatr Dermatol. 2017 Jan 23. doi: 10.1111/pde.13070. [Epub ahead of print]
PMID: 28111793
Similar articles

7. The impact of **dermoscopy** on melanoma detection in the practice of dermatologists in Europe: Results of a pan-European survey.
Forsea AM, Tschandl P, Zalaudek I, Del Marmol V, Soyer HP; Eurodermoscopy Working Group., Argenziano G, Geller AC.
J Eur Acad Dermatol Venereol. 2017 Jan 21. doi: 10.1111/jdv.14129. [Epub ahead of print]
PMID: 28109068
Similar articles

9. **Dermoscopy** of Granuloma Annulare: A Clinical and Histological Correlation Study.
Errichetti E, Lallas A, Apalla Z, Di Stefani A, Stinco G.
Dermatology. 2017 Jan 19. doi: 10.1159/000454857. [Epub ahead of print]
PMID: 28099955

Results by year

Download CSV

Related searches
dermoscopy melanoma
dermoscopy pigmented
nevus dermoscopy
dermoscopy lichen
dermoscopy nail

PMC Images search for dermoscopy




Titles with your search terms
Dermoscopy of Langerhans cell histiocytosis. [J Am Acad Dermatol. 2017]
Dermoscopy of giant juvenile xanthogranuloma. [J Am Acad Dermatol. 2017]
Dermoscopy of cutaneous involvement by multiple myeloma. [J Am Acad Dermatol. 2017]
See more...

Find related data
Database: Select

Search details
```
"dermoscopy"[MeSH Terms] OR
"dermoscopy"[All Fields]
```

Recent Activity
Turn Off Clear
Dermoscopy of Granuloma Annulare: A Clinical and Histological Correlation S PubMed

- F 13 anni - regione scapolare dx
- Note: lesione notata dai genitori da meno di un anno, in accrescimento

SCUOLA DERMATOLOGICA

SERGIO CHIMENTI

SCUOLA DERMATOLOGICA
SERGIO CHIMENTI

1. Melanoma
2. Melanoacantoma
3. Melanocitoma
4. Nevo blu
5. Dermatofibroma aneurismatico
6. Angiocheratoma solitario

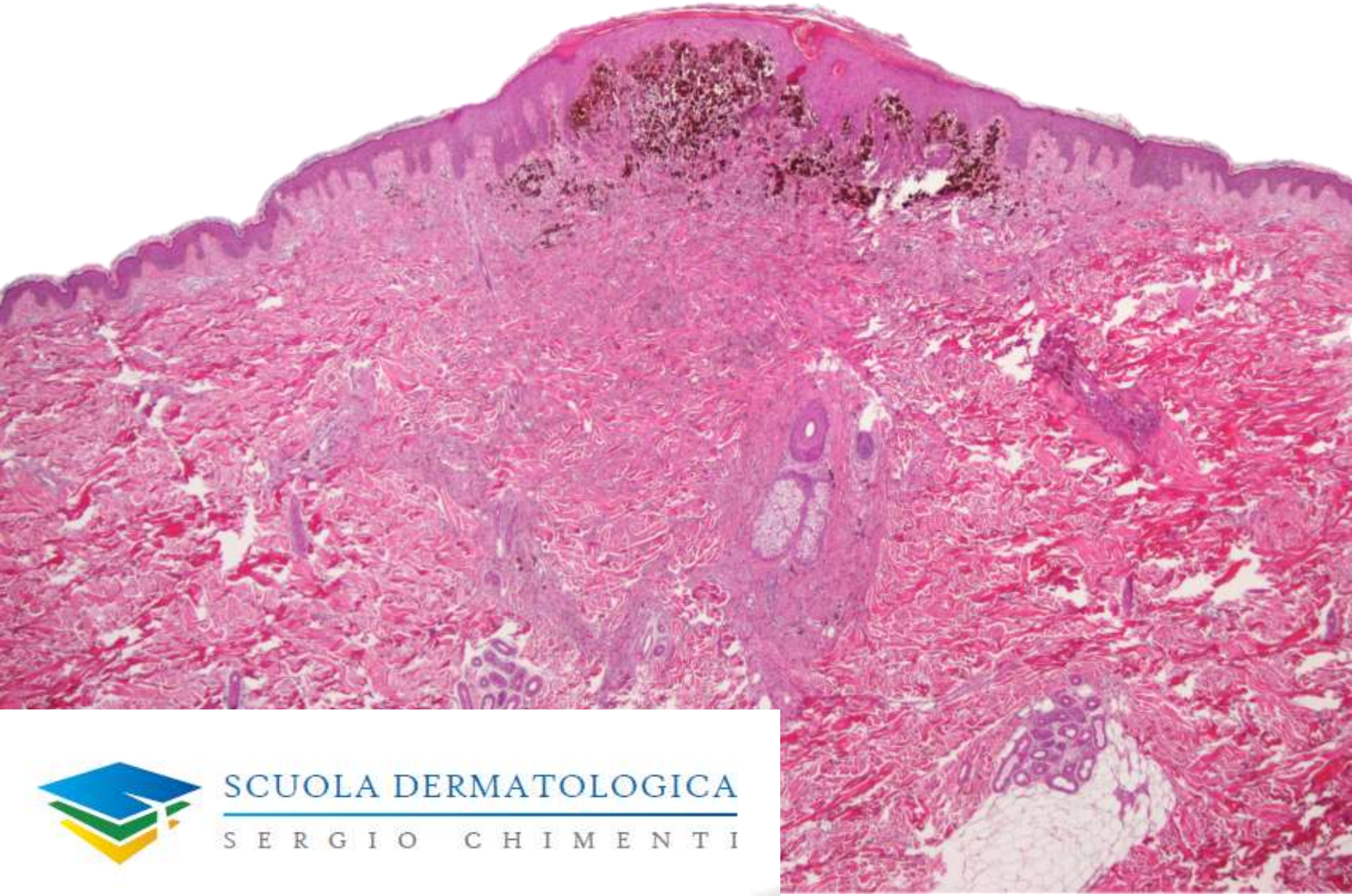

SCUOLA DERMATOLOGICA

SERGIO CHIMENTI

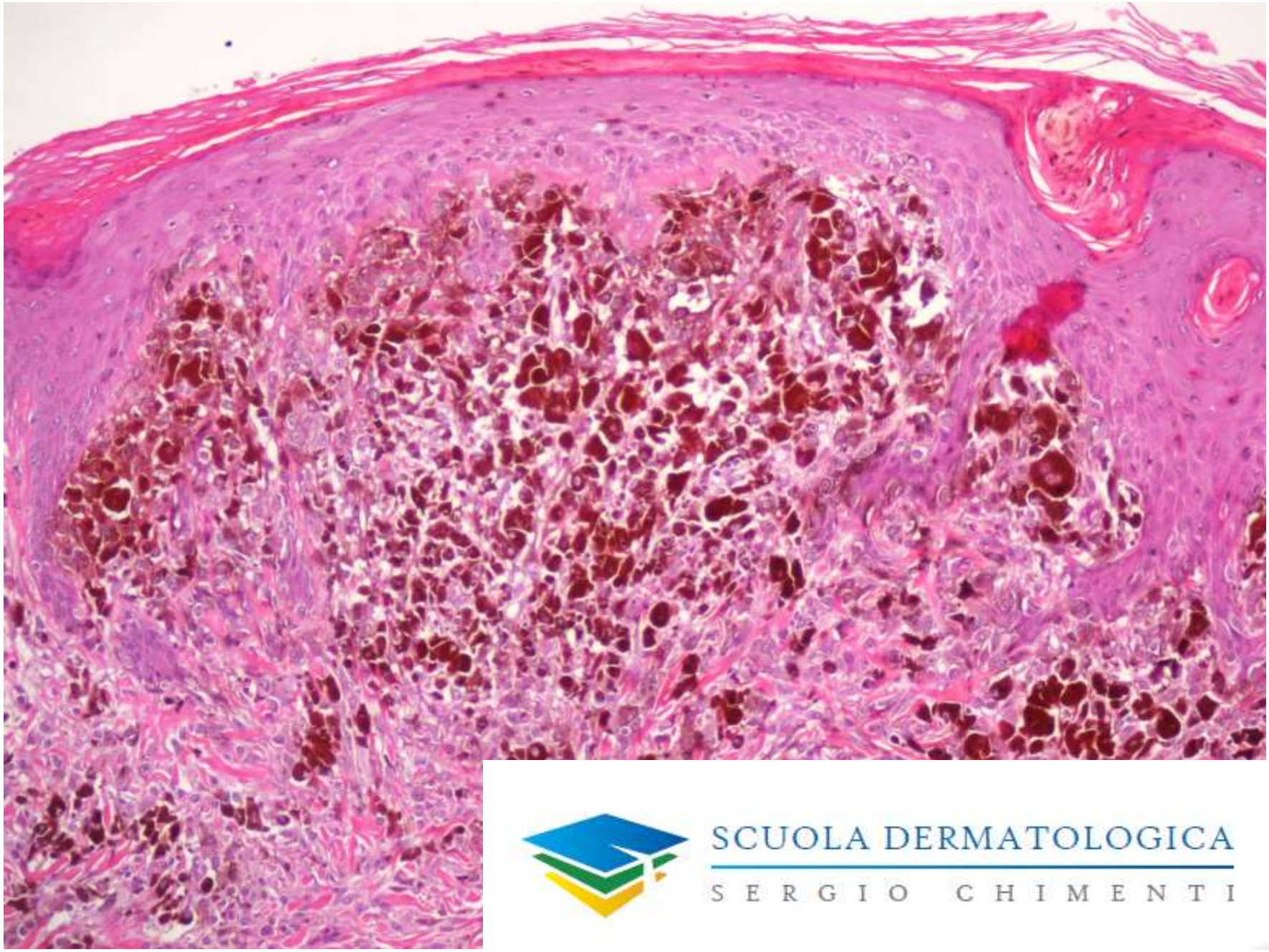

SCUOLA DERMATOLOGICA

SERGIO CHIMENTI

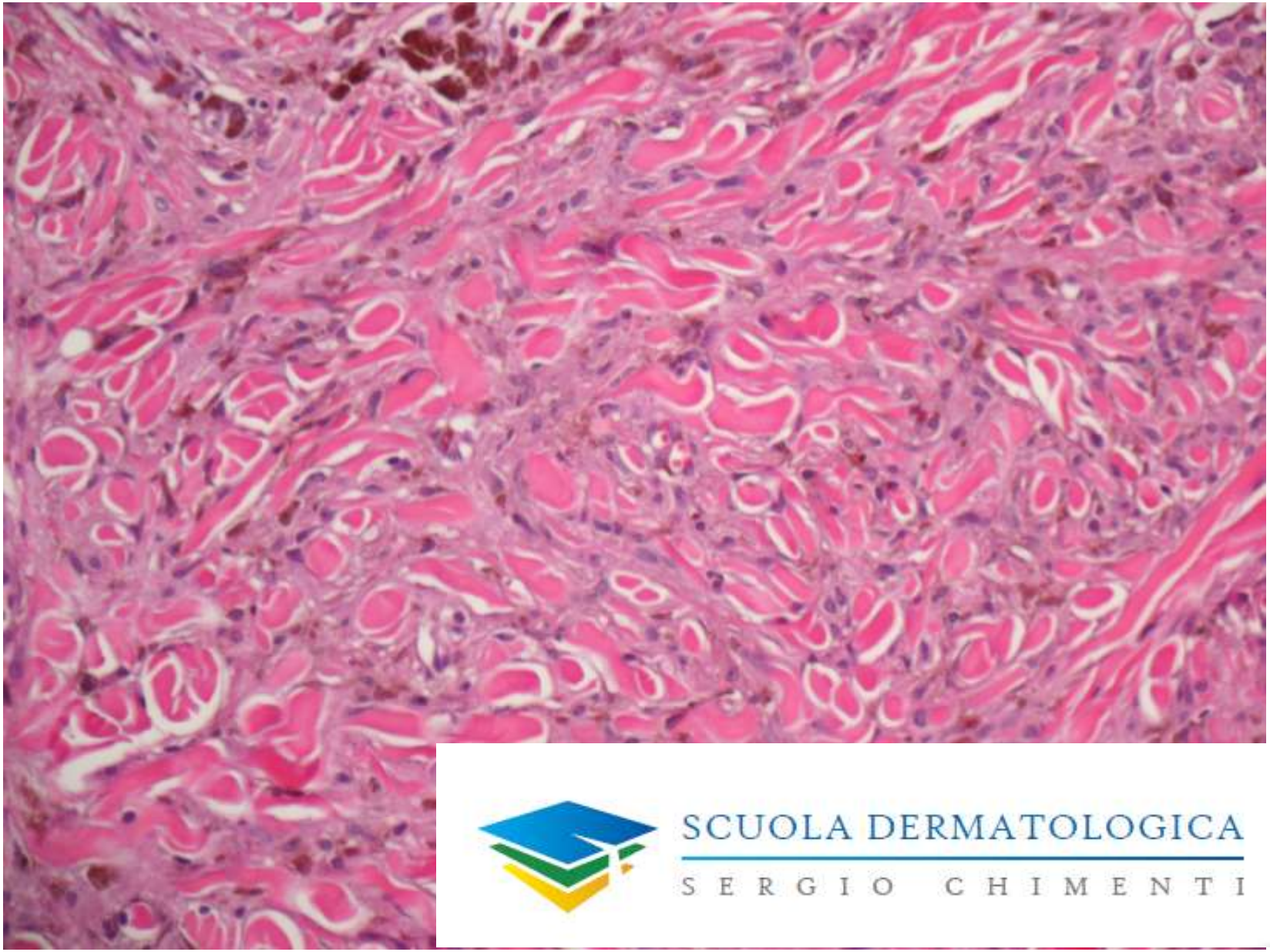

SCUOLA DERMATOLOGICA

SERGIO CHIMENTI

Am J Surg Pathol • Volume 28, Number 1, January 2004

Pigmented Epithelioid Melanocytoma

A Low-grade Melanocytic Tumor With Metastatic Potential Indistinguishable From Animal-type Melanoma and Epithelioid Blue Nevus

Artur Zembowicz, MD, PhD, J. Aidan Carney,† and Martin C. Mihm**

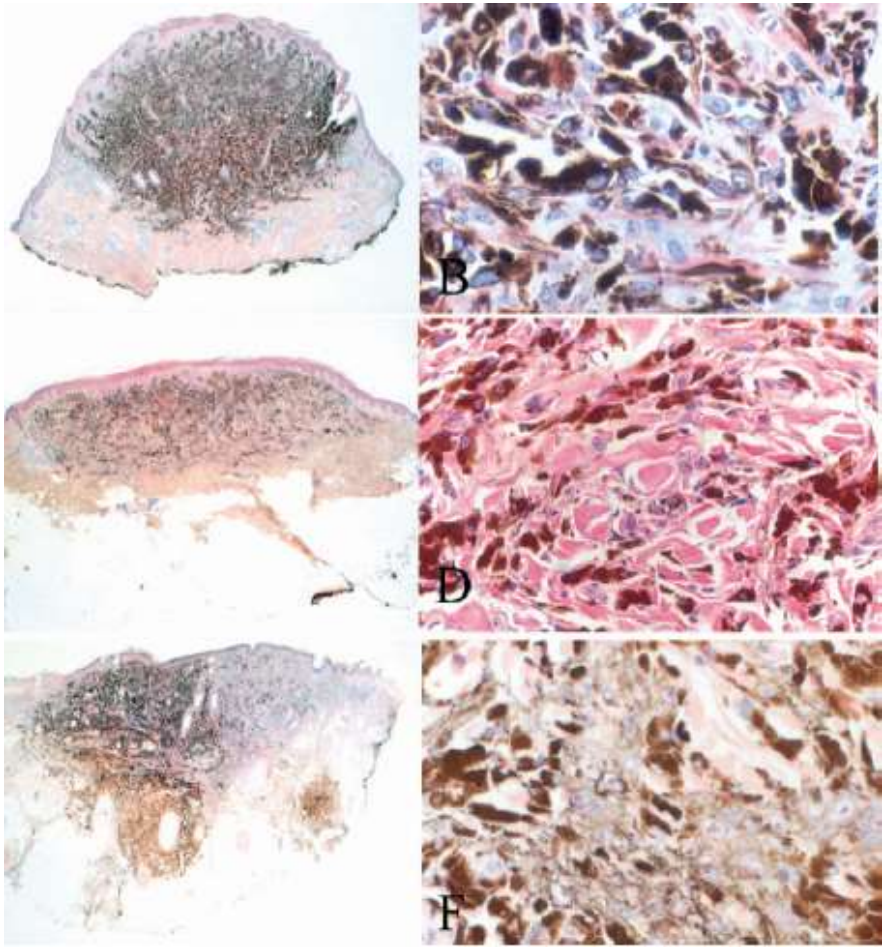

Pigmented epithelioid melanocytoma is a term that encompasses melanocytic tumours showing overlapping features between:

- an atypical epithelioid blue naevus (first described in Carney complex and then also as sporadic)
- a low-grade 'animal-type melanoma' or 'pigment-synthesizing melanoma'

TABLE 2. Clinical Data Concerning 11 Patients With PEM and Sentinel Lymph Node Metastases

Case No.	Age (yr)	Sex	Ethnicity	Site	Clinical Impression	Completion Lymphadenectomy	Follow-up (mo)
6	27	M	White	Scalp	Blue nodule, probably combined nevus	Positive	36
7	40	M	White	Back	Pigmented nevus	Negative	28
11	46	M	White	Toe	Atypical blue nevus	Positive	6
12	21	F	Black	Thigh	Not stated	Negative	24
13	0.8	F	Black	Scalp	Changing congenital nevus	Positive	35
14	32	M	Hispanic	Upper arm	Black nevus, changing	Negative	25
17	18	M	White	Scalp	Seborrheic keratosis, Poroma, pilomatrixoma, Spitz nevus	Positive	16
24	9	M	White	Scalp	Melanoma	Positive	45
26	38	M	Hispanic	Calf	Tumor	Negative	8
28	9	F	White	Face	Not stated	Negative	20
30	31	M	Unknown	Shoulder	Not stated	Negative	10

- Involvement of the regional nodes has been reported in up to 46% of cases
- No further spread of the disease

Nevus/Melanocytoma/Melanoma

An Emerging Paradigm for Classification of Melanocytic Neoplasms?

Artur Zembowicz, MD, PhD; Richard A. Scolyer, MD, FRCPA, FRCPath

• *Context.*—Until recently, the prevailing paradigm in classification and clinical management of melanocytic proliferations mandated dichotomous classification of all melanocytic lesions as either entirely benign (nevus) or entirely malignant (melanoma). However, some diagnostically challenging lesions cannot be unequivocally classified as nevus or melanoma by histologic evaluation of the primary tumor. Such lesions have been referred to as borderline or melanocytic tumors of uncertain malignant potential.

Objective.—To review and update the problem of diagnostically difficult melanocytic proliferations and recent concepts regarding borderline melanocytic tumors.

Data Sources.—Published literature and personal experience of the authors.

Conclusions.—Preliminary evidence indicates that it may be appropriate to expand the classification scheme of melanocytic neoplasms to include a third diagnostic category of melanocytic lesions of intermediate malignant potential that are capable of metastasis to regional lymph nodes but have limited potential for distant spread. We propose the term *melanocytoma* for this group of lesions. We believe that a nevus/melanocytoma/melanoma paradigm may provide a useful intellectual framework to understand, research, and clinically manage borderline melanocytic tumors.

(*Arch Pathol Lab Med.* 2011;135:300–306)

Histologic Categories of Borderline Melanocytic Lesions[a]

	Histologic Category	Differential Diagnosis
1	Severely atypical dermoepidermal nevomelanocytic proliferation with borderline features of radial-growth-phase malignant melanoma	Dysplastic nevus versus superficial spreading or lentigo maligna melanoma
2	Severely atypical dermoepidermal nevomelanocytic proliferation with borderline features of early vertical-growth-phase melanoma	Dysplastic nevus versus superficial spreading or lentigo maligna melanoma
3	Severely atypical intraepidermal epithelioid cell melanocytic dysplasia mimicking superficial spreading melanoma	Dysplastic nevus versus superficial spreading or lentigo maligna melanoma
4	Atypical lentiginous melanocytic proliferation/de novo melanocytic dysplasia mimicking lentigo maligna	Dysplastic nevus versus lentigo maligna melanoma
5	Severely atypical superficial compound Spitz tumor mimicking superficial spreading melanoma in radial or early vertical growth	Spitz nevus versus spitzoid melanoma
6	Severely atypical spitzian proliferation (atypical Spitz tumor) mimicking spitzian melanoma	Atypical Spitz nevus versus spitzoid melanoma
7	De novo dermal-based epithelioid melanocytic dysplasia	Nevus versus melanoma arising in a nevus
8	Borderline lesions mimicking nevoid melanoma	Nevus versus nevoid melanoma versus nodular melanoma
9	Severely atypical dermal-based melanocytic proliferation *without* criteria for nevoid melanoma/minimal deviation melanoma, spitzian type	Deep-penetrating nevus, blue nevus, clonal nevus versus melanoma

[a] Derived from data in Crowson et al.[7]

Pigmented epithelioid melanocytoma: clinical, dermoscopic and histopathological features

Research letter

E. Moscarella[1]

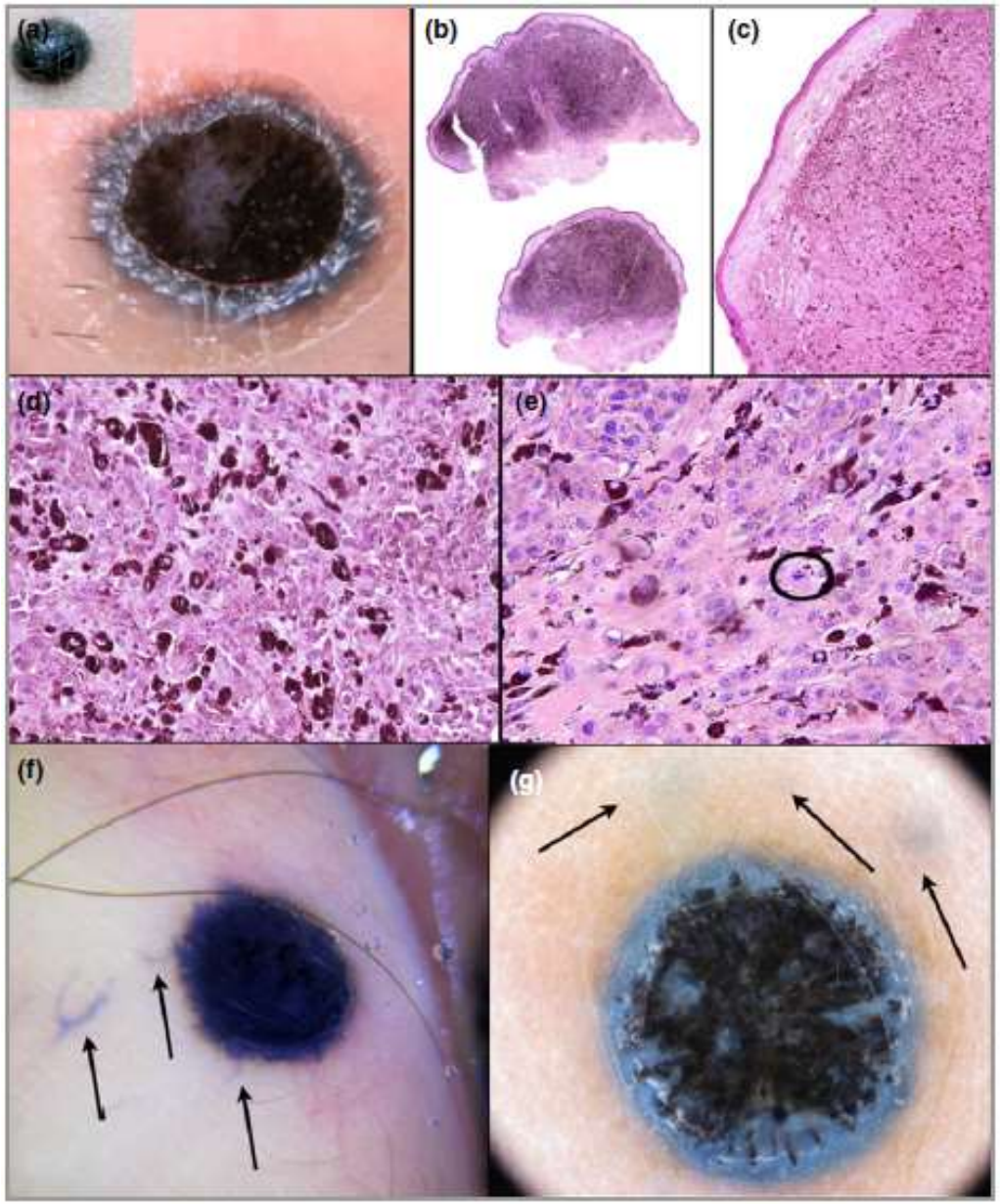

Dermoscopic features:

- Structureless blue pigmentation
- Crystalline structures (polarized)
- Black color in the center
- Brown color at periphery possible
- *Lesions were excised because they were reported as growing*

British Journal of Dermatology (2016) **174**, pp1115–1117

Management of Melanocytoma:

- Second opinion in un altro centro di riferimento di Dermatopatologia

Complesso Columbus
Fondazione Policlinico Universitario Agostino Gemelli

Struttura complessa di Istopatologia e Citodiagnosi
Direttore : Prof. G. Massi

Via G. Moscati 31-33 00168 Roma Tel: 06-3503751 Fax: 06-3503889 E-Mail: anatomiapatologica@h-columbus.it

Data emissione referto: 26/09/2016
Data ricezione campi
Paziente:
Medico: Di Stefani
Nosologico: c.a. 868/2016 DERMATOLOGIA - APA

Procedura : BIOPSIA ASPORTAZIO
Topografia : Interscapolare des

DIAGNO

SCUOLA DERMATOLOGICA SERGIO CHIMENTI

diffusione
do sentinella ne' allargamento
o periodico a distanza di tempo e pronta
ati recidive.

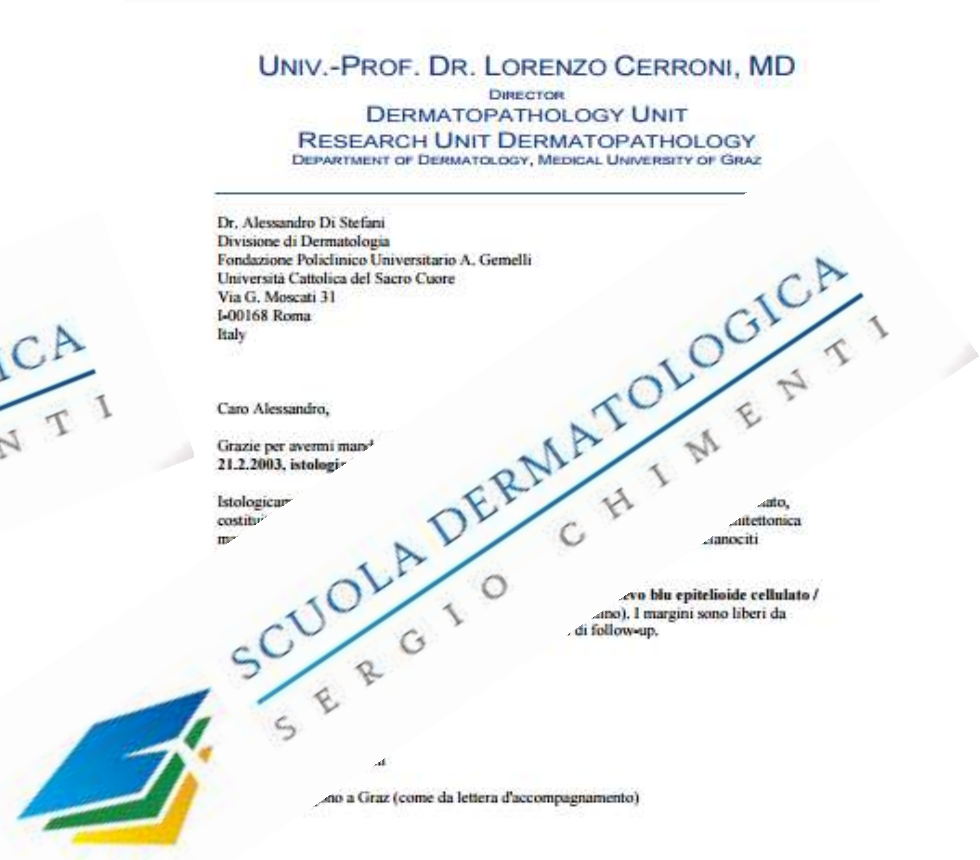

UNIV.-PROF. DR. LORENZO CERRONI, MD
DIRECTOR
DERMATOPATHOLOGY UNIT
RESEARCH UNIT DERMATOPATHOLOGY
DEPARTMENT OF DERMATOLOGY, MEDICAL UNIVERSITY OF GRAZ

Dr. Alessandro Di Stefani
Divisione di Dermatologia
Fondazione Policlinico Universitario A. Gemelli
Università Cattolica del Sacro Cuore
Via G. Moscati 31
I-00168 Roma
Italy

Caro Alessandro,

Grazie per avermi man
21.2.2003, istologi

Istologica
costit
m

ato,
itettonica
anociti

vo blu epitelioide cellulato /
no). I margini sono liberi da
di follow-up.

no a Graz (come da lettera d'accompagnamento)

SCUOLA DERMATOLOGICA SERGIO CHIMENTI

Management of Melanocytoma:

- Approccio discusso e condiviso col paziente/genitori
- Ampliamento chirurgico (margini)
- NON è necessario il linfonodo sentinella
- Follow-up clinico/strumentale (eco)

Atypical Spitz tumours and sentinel lymph node biopsy: a systematic review

Lancet Oncol 2014; 15: e178–83

Aimilios Lallas, Athanassios Kyrgidis, Gerardo Ferrara, Harald Kittler, Zoe Apalla, Fabio Castagnetti, Caterina Longo, Elvira Moscarella, Simonetta Piana, Iris Zalaudek, Giuseppe Argenziano

Sentinel lymph node biopsy has been proposed as a diagnostic method for estimation of the malignant potential of atypical Spitz tumours. However, although cell deposits are commonly detected in the sentinel lymph nodes of patients with atypical Spitz tumours, their prognosis is substantially better than that of patients with melanoma and positive sentinel lymph node biopsies. We did a systematic review of published reports to assess the role of sentinel lymph node biopsy as a prognostic method in the management of atypical Spitz tumours. The results of our analysis did not show any prognostic benefit of sentinel lymph node biopsy; having a positive sentinel lymph node does not seem to predict a poorer outcome for patients with atypical Spitz tumours. These findings indicate that, especially in the paediatric population, it might be prudent initially to use complete excision with clear margins and careful clinical follow-up in patients with atypical Spitz tumours.