TECNOLOGIA e INNOVAZIONE TERAPEUTICA in DERMATOLOGIA

dalla ricerca alla pratica clinica

9ª edizione

3-4 Novembre 2016

ROMA

PSORIASI E ALOPECIA

Francesco Tassone

Clinica Dermatologica
Fondazione Policlinico A. Gemelli
Università Cattolica del S. Cuore
Roma

CASISTICA CLINICA

- PAZIENTE 1

- Pz maschio, 49 aa
- Psoriasi dall'età di 41 anni; familiarità (fratello)
- Terapie precedenti: corticosteroidi topici, CsA, Adalimumab ed Etanercept
- Alopecia Areata comparsa dopo 12 mesi di terapia con Etanercept

CASISTICA CLINICA

- PAZIENTE 1

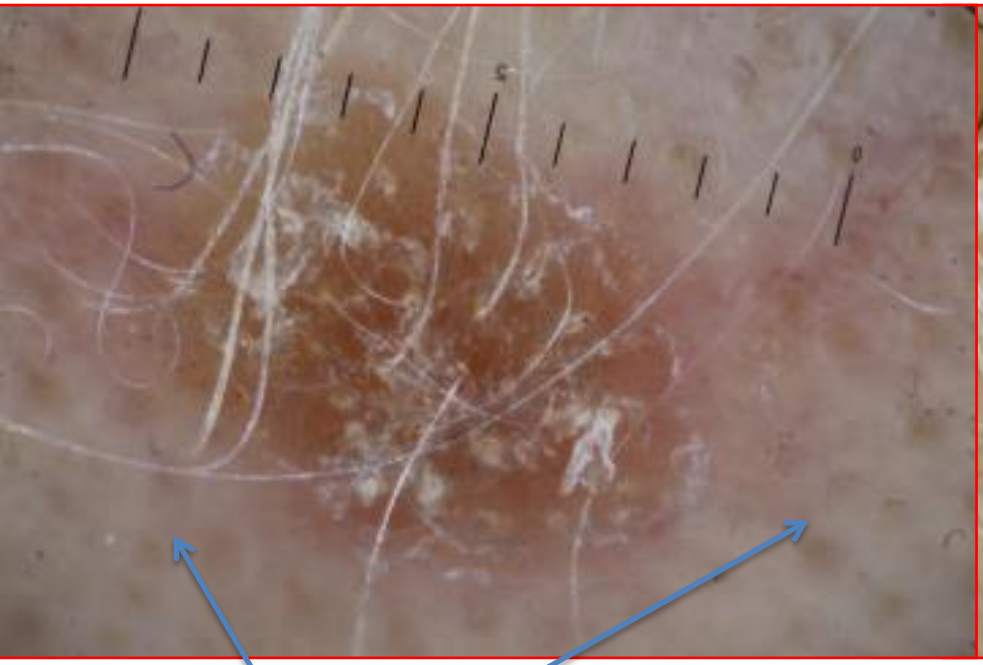

l'alopecia areata risparmia la placca psoriasica

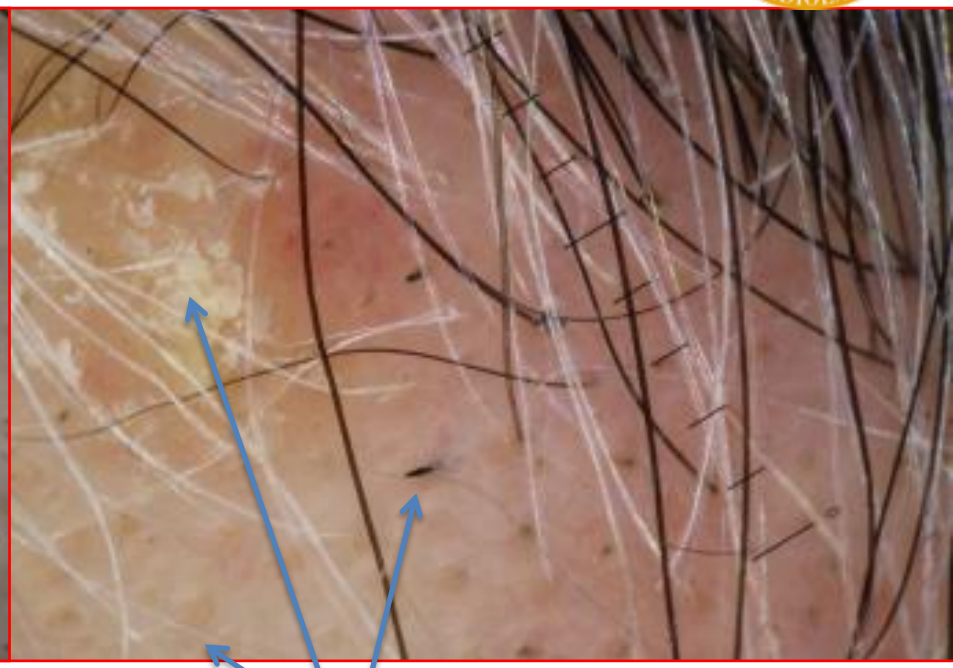

squame bianco-giallastre accanto a broken hairs e yellow dots

CASISTICA CLINICA

- PAZIENTE 1

•Lieve Miglioramento dopo applicazione di CCS ad alta potenza (Clobetasolo in occlusiva)

CASISTICA CLINICA

- PAZIENTE 2

- Pz maschio di 40 anni
- Psoriasi dall'età di 30 anni, alopecia areata totale dall'età di 32 anni, poi diventata universale
- Terapie per la Psoriasi: CSA, Acitretina, Fototerapia, Adalimumab, con numerose recidive dell'AA

CASISTICA CLINICA

PAZIENTE 2 (TRICOSCOPIA)

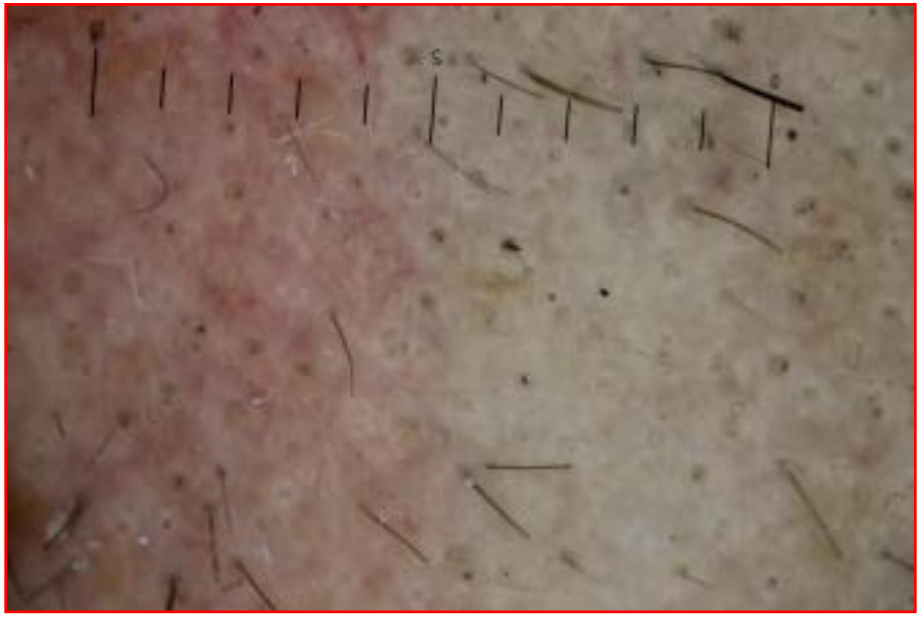

- Presenza di broken hair e yellow dots, con minimi segni di psoriasi del CC
- Attualmente il paziente è in terapia con Ustekinumab, dopo lo switch da Adalimumab per ricaduta dell'AAU.

CASISTICA CLINICA

- <u>PAZIENTE 2</u>

- Moderata ricrescita dopo un anno di terapia con Ustekinuamab.

CASISTICA CLINICA

- <u>PAZIENTE 3</u>

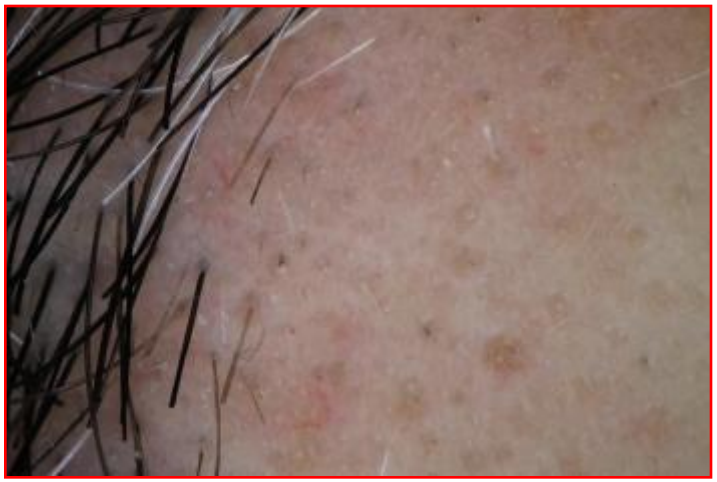

- Paziente maschio, 46 aa, Pso e PsA dall'età di 22 anni
- In terapia continuativa con Ustekinumab da 4 anni, comparsa di singola chiazza di alopecia areata della barba
- Non è stato sospeso UST e sono stati associati CCS topici ad alta potenza per l'AA

CASISTICA CLINICA

- PAZIENTE 4

- Donna di 59 anni
- Psoriasi dall'età di 30 anni, sempre in forma lieve, trattata esclusivamente con terapie topiche

- *Settembre 2015* → Comparsa di quadro eritrodermico (PASI 43,2) con iperpiressia a 39,5 C e astenia, comparso in seguito ad evento luttuoso

Giunge in PS e Ospedalizzazione

ANAMNESI

- Pz ipertesa in terapia, con insufficienza renale lieve
- Non malattie infettive concomitanti
- Funzionalità epatica: nella norma
- Esami ematochimici di routine: nella norma

ALGORITMO TERAPEUTICO PER L'ERITRODERMIA PSORIASICA

First line‡
Cyclosporine*
Infliximab*
Acitretin
Methotrexate

‡ Supportive care with topical therapy should be used in conjunction with systemic treatment
* Faster onset, may be more appropriate for acute or severe presentations

↓

Second line
Etanercept
Combination therapy*
* See discussion for details

Misha Rosenbach, Sylvia Hsu, Neil J. Korman, Mark G. Lebwohl, Melodie Young, Bruce F. Bebo Jr., Abby S. Van Voorhees

Treatment of erythrodermic psoriasis: From the medical board of the National Psoriasis Foundation

Journal of the American Academy of Dermatology, Volume 62, Issue 4, 2010, 655–662

Aspetti clinici

Remissione quasi completa dopo 10 giorni di terapia medica con CCS ev seguita da 1 mese di terapia domiciliare con Acitretina 25 mg/die

Novembre2015

FOLLOW UP

✓Presenza di psoriasi residua a livello del cuoio capelluto

Comparsa di chiazze di ***alopecia areata***, con segni dermatoscopici di attività, <50% dello scalpo, accanto alle chiazze di psoriasi

✓ Notevole coinvolgimento psichico per la paziente

Aspetti clinici

Dicembre 2015

Aspetti dermoscopici

LINEE GUIDA SULL'AA

- **CCS topici di alta potenza (classe VI)**

Type of AA	Treatment suggestions	
Short-standing, limited patchy AA	No treatment *or*	
	Topical corticosteroids:	Clobetasol-foam twice daily
Longstanding patchy AA	Topical corticosteroids	Clobetasol-foam twice daily
		Clobetasol-ointment occlusive overnight
	Intralesional corticosteroids	
	Topical immunotherapy with diphencyprone or SADBE	
AAT / AAU	Topical immunotherapy with diphencyprone or SADBE	
	Clobetasol-ointment occlusive overnight	

Da "Hair Growth and disorders", Tosti et al.

LINEE GUIDA SULLA PSORIASI DEL CC

- CCS topici di alta potenza (classe VI)

J Eur Acad Dermatol Venereol. 2009 Dec;23(12):1435-44. doi: 10.1111/j.1468-3083.2009.03372.x. Epub 2009 Jul 15.

Scalp psoriasis: European consensus on grading and treatment algorithm.

Ortonne J[1], Chimenti S, Luger T, Puig L, Reid F, Trüeb RM.

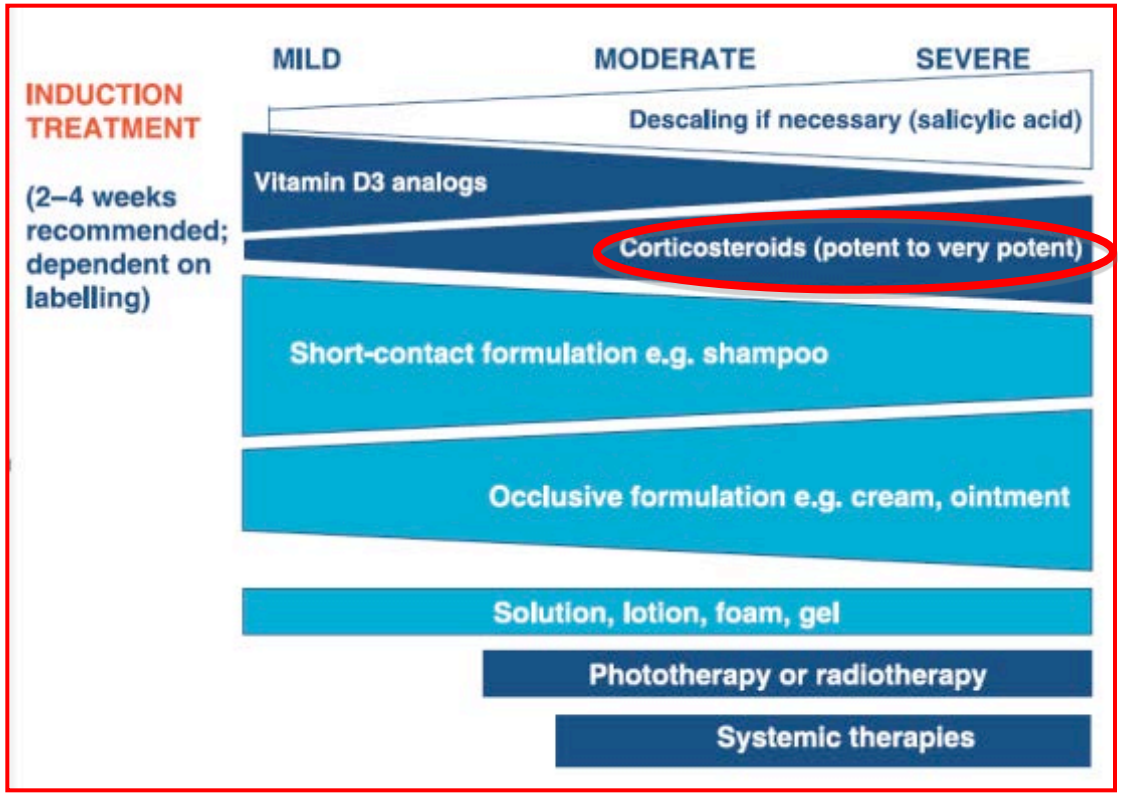

FOLLOW UP

✓ *Gennaio 2016:*

✓Scomparsa della psoriasi residua a livello del cuoio capelluto.

✓Estensione delle chiazze di alopecia areata, con segni dermatoscopici di attività, <50% dello scalpo.

Aspetti clinici

Gennaio 2016

LINEE GUIDA SULL' AA

Table 15.6 Treatment suggestions for different types of AA

Type of AA	Treatment suggestions	
Short-standing, limited patchy AA	No treatment *or*	
	Topical corticosteroids:	Clobetasol-foam twice daily
Longstanding patchy AA	Topical corticosteroids	Clobetasol-foam twice daily
		Clobetasol-ointment occlusive overnight
	Intralesional corticosteroids	
	Topical immunotherapy with diphencyprone or SADBE	
AAT / AAU	Topical immunotherapy with diphencyprone or SADBE	
	Clobetasol-ointment occlusive overnight	

✓Terapia con CCS intralesionali (Triamcinolone 40 mg/ml + SF con diluizione 1:2, una volta al mese, per 3 mesi.

Da "Hair Growth and disorders", Tosti et al.

Aspetti clinici

Febbraio 2016

Aspetti clinici

Marzo 2016

Aspetti clinici

Prima e dopo

Aspetti dermoscopici

Prima e dopo

Tabella riassuntiva

Sesso	Età	Psoriasi	Terapia	Alopecia	Terapia	Risultato
M	49	Da 8 aa	Eta	Patchy	tCCS	RP
M	40	Da 10 aa	Ada	AAU	Sosp.	RC
M	46	Da 24 aa	Ust	Patchy	tCCs	RP
F	59	Da 29 aa	Acitret	Patchy/AAT	ilCCS	RC

RP: remissione parziale
RC: remissione completa
tCCS: corticosteroidi topici (Clobetasolo)
ilCCS: corticosteroidi intralesionali (Triamcinolone)

«ALOPECIA PSORIASICA»

Clinical dermatology • **Review article**

CED
Clinical and Experimental Dermatology

CPD

Psoriatic alopecia

S. M. C. George,[1] M. R. Taylor[2] and P. B. J. Farrant[3]

[1]*Department of Dermatology, Eastbourne District General Hospital, Eastbourne, UK; and* [2]*Departments of Pathology and* [3]*Dermatology, Brighton and Sussex University Hospitals NHS Trust, Brighton, UK*

1. Correlata alla psoriasi di per sé (lesionale)

2. Correlata alle terapie per la psoriasi

3. Correlata a malattie autoimmuni concomitanti (es AA)

ALOPECIA “LESIONALE”

- Compare 6 settimane dopo la insorgenza della psoriasi e persiste in media per ulteriori 6 settimane
- Media di capelli persi al giorno: 480; dopo lo shampoo: 1000 (vs 80 capelli al giorno in soggetto sano)
- Riscontrato un decremento nella densità pilare con aumento del numero di bulbi distrofici all’interno delle placche
- All’interno delle lesioni > n. di capelli in fase Telogen → possibile *telogen effluvium localizzato*, confinato alle placche psoriasiche

L' ALOPECIA "LESIONALE" E' REVERSIBILE …

Alopecia «lesionale», secondaria a psoriasi severa del CC

Completa ricrescita

- Al tricogramma aumento dei capelli in Telogen intorno al 63% in fase acuta (vn: <10%)

- Ricrescita quasi completa nella maggioranza dei casi, soprattutto in concomitanza con la clearance cutanea della psoriasi

…MA NON SEMPRE

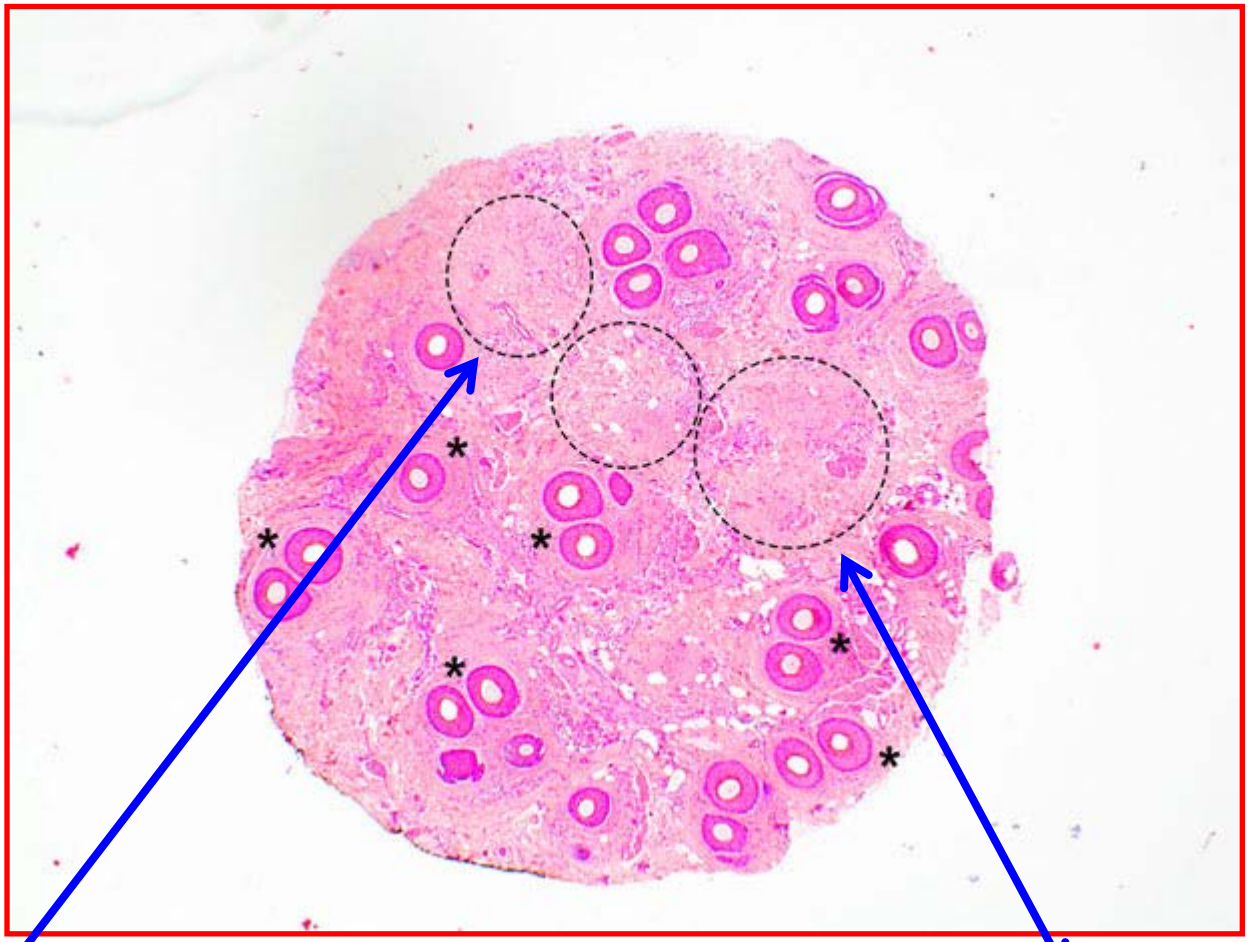

12%

Riduzione del n. delle gh. sebacee

Fibrosi diffusa con scomparsa dei follicoli

RUOLO DELLE TERAPIE PER LA PSORIASI

- La *frizione* nell'applicazione di terapie topiche può determinare un distacco dei capelli in Telogen
- Fino al 6% dei pz in terapia con methotrexate può sviluppare una forma di alopecia (e.g. Telogen Effluvium)
- Dal 13 al 73% dei pazienti in terapia con Retinoidi, può sviluppare alopecia, che è dose-dipendente, e in particolare con pattern di Telogen Effluvium o Alopecia Areata
- Diversi case reports di associazione fra anti-TNF e comparsa di Alopecia areata o LPP

1. George SM, Taylor MR, Farrant PB. Psoriatic alopecia. Clin Exp Dermatol. 2015 Oct;40(7):717-21. doi: 10.1111/ced.12715. Epub 2015 Jul 23.

RETINOIDI E AA

Acitretin-induced alopecia areata: a case report

J Invest Dermatol. 2013 Feb;133(2):285-6. doi: 10.1038/jid.2012.441.

Retinoids putting the "a" in alopecia.

Holler PD[1], Cotsarelis G.

Author information

Abstract

Vitamin A (vitA) has many roles in human biology. With respect to hair, knockout mice for vitA receptor, hairless, and vitamin D genes have similar phenotypes, and follicle loss occurs during catagen. Hypovitaminosis A from inadequate vitA intake causes hair loss. This work suggests that dietary vitA may have a role in precipitating and maintaining alopecias as well.

J Invest Dermatol. 2013 Feb;133(2):334-43. doi: 10.1038/jid.2012.344. Epub 2012 Sep 27.

Endogenous retinoids in the pathogenesis of alopecia areata.

Duncan FJ[1], Silva KA, Johnson CJ, King BL, Szatkiewicz JP, Kamdar SP, Ong DE, Napoli JL, Wang J, King LE Jr, Whiting DA, McElwee KJ, Sundberg JP, Everts HB.

Author information

Abstract

Alopecia areata (AA) is an autoimmune disease that attacks anagen hair follicles. Gene array in graft-induced C3H/HeJ mice revealed that genes involved in retinoic acid (RA) synthesis were increased, whereas RA degradation genes were decreased in AA compared with sham controls. This was confirmed by immunohistochemistry in biopsies from patients with AA and both mouse and rat AA models. RA levels were also increased in C3H/HeJ mice with AA. C3H/HeJ mice were fed a purified diet containing one of the four levels of dietary vitamin A or an unpurified diet 2 weeks before grafting and disease progression followed. High vitamin A accelerated AA, whereas mice that were not fed vitamin A had more severe disease by the end of the study. More hair follicles were in anagen in mice fed high vitamin A. Both the number and localization of granzyme B-positive cells were altered by vitamin A. IFNγ was also the lowest and IL13 highest in mice fed high vitamin A. Other cytokines were reduced and chemokines increased as the disease progressed, but no additional effects of vitamin A were seen. Combined, these results suggest that vitamin A regulates both the hair cycle and immune response to alter the progression of AA.

FARMACI BIOLOGICI E ALOPECIA

Journal of Dermatological Case Reports

Alopecia areata developing paralell to improvement of psoriasis during ustekinumab therapy

Monika Słowińska[1], Agnieszka Kardynal[1], Olga Warszawik[1], Joanna Czuwara[1], Lidia Rudnicka[1,2,3]

1. Dept. Dermatology CSK MSWiA, Warsaw, Poland
2. Faculty of Health Sciences, Warsaw Medical University, Warsaw, Poland
3. Polish Academy of Sciences, Warsaw, Poland

3. Posten W, Swan J. Recurrence of alopecia areata in a patient receiving etanercept injections. *Arch Dermatol.* 2005;141:1?80-?60.
4. Miscuali C, Peluso AM, Cameli N, Tosti A. Occurrence of alopecia areata in a patient receiving systemic cyclosporine A. *Arch Dermatol.* 1996;132:843-844.
5. Gupta AK, Ellis C, Cooper K. Oral cyclosporine for the treatment of alopecia areata: a clinical and immunohistochemical analysis. *J Am Acad Dermatol.* 1990; 22:242-250.

Development of Alopecia Areata Universalis in a Patient Receiving Adalimumab

Alopecia areata (AA) is characterized by nonscarring patchy hair loss on the scalp that can progress to involve the entire scalp (AA totalis) and eventually the entire body (AA universalis). Increasing evidence indicates that multiple cytokines—such as tumor necrosis factor (TNF) α, interleukin-1α, and interferon-γ—might be relevant to the autoimmune pathogenesis of AA because peribulbar inflammation is believed to inhibit hair growth by the actions of inflammatory cytokines.[1] Novel biologic therapies that block TNF-α–mediated processes are used in the treatment of autoimmune diseases, including AA.[2] Adalimumab, a human monoclonal TNF-α antibody, is administered by subcutaneous injection for the treatment of rheumatoid arthritis. Owing to the suspected involvement of TNF-α in the pathogenesis of AA, one might expect adalimumab therapy to be beneficial for patients with AA. We describe a patient who developed rapidly progressive AA universalis during treatment with adalimumab for rheumatoid arthritis.

Report of a Case. A 23-year-old woman was seen with a 2-year history of patchy hair loss. Initially, she was diagnosed as having patchy-type AA, which after treatment with topical dexamethasone solution, 0.1%,

Figure 1. Recurrence of patchy-type alopecia areata after 2 months of therapy with adalimumab.

Letter: Alopecia areata during ustekinumab administration: Co-existence or an adverse reaction?

Constantinos Verros[1], Efstathios Rallis[2], Mark Crowe[3]

Dermatology Online Journal 18 (7): 14 323"233E3E22231"3

1. Dermatologist, Private practice, Tripolis, Greece
2. Veterans Administration Hospital (NIMTS), Department of Dermatology, Athens Greece
3. Dermatologist, Private practice, Puyallup, Washington

FARMACI BIOLOGICI E ALOPECIA: come comportarsi?

Alopecia areata occurring during anti-TNF therapy: A national multicenter prospective study

- 29 pazienti in terapia con anti-TNF e AA
- 11 Adalimumab, 10 Infliximab, 8 Etanercept
- 14 hanno sospeso terapia
- 15 hanno continuato terapia

Table II. Outcome of alopecia areata with withdrawal or maintenance of TNF blocker

Outcome	TNF blocker withdrawn (n = 14)	TNF blocker maintained (n = 15)	*P* value*
Specific treatment for AA	10 (71%)	10 (67%)	>.99
Mean follow-up	23.8 mo	24.2 mo	.52
AA worsening or stabilization	3 (21%)	4 (27%)	>.99
AA PR	4 (28%)	4 (27%)	>.99
AA CR	7 (50%)	7 (47%)	>.99
Mean time to reach PR or CR	5.5 mo	4.6 mo	.48

AA, Alopecia areata; *CR*, complete remission; *PR*, partial remission; *mo*, months; *TNF*, tumor necrosis factor.
*Fisher's exact test or Mann-Whitney test.

Non effettuare una sospensione sistematica del farmaco ma valutare ciascun caso individualmente; considerare switch di classe.

ref

ALOPECIA AREATA E PSORIASI

- Pazienti con psoriasi hanno un rischio 2 volte maggiore di sviluppare alopecia areata (OR: 2,5)
- «Duelling cytokines» alla base dell'associazione, con possibile interazione Th-1/Th-17, con aumentata espressione di IL-12 e altre citochine Th1

Fenomeno di Renbok

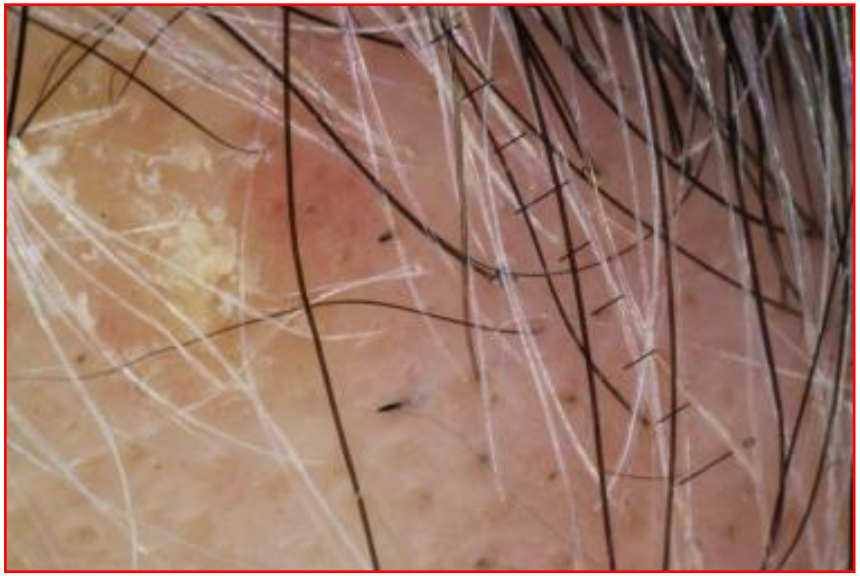

1. George SM, Taylor MR, Farrant PB. Psoriatic alopecia. Clin Exp Dermatol. 2015 Oct;40(7):717-21. doi: 10.1111/ced.12715. Epub 2015 Jul 23.

Fenomeno di Renbok

Two Birds that Exclude Each Other: The Renbök Phenomenon

Journal of Investigative Dermatology (2015) **135**, 1180; doi:10.1038/jid.2014.509; published online 8 January 2015

"This interesting clinical finding of exclusion or withdrawal of one inflammatory condition in the presence of another has been previously noted and has been described as a reverse Koebner reaction or Renbok phenomenon."

Innovazione terapeutica…

J Invest Dermatol. 2014 Dec;134(12):2988-90. doi: 10.1038/jid.2014.260. Epub 2014 Jun 18.

Killing two birds with one stone: oral tofacitinib reverses alopecia universalis in a patient with plaque psoriasis.

Craiglow BG[1], King BA[1].

⊕ **Author information**

Comment in

Two birds that exclude each other: the Renbök phenomenon. [J Invest Dermatol. 2015]

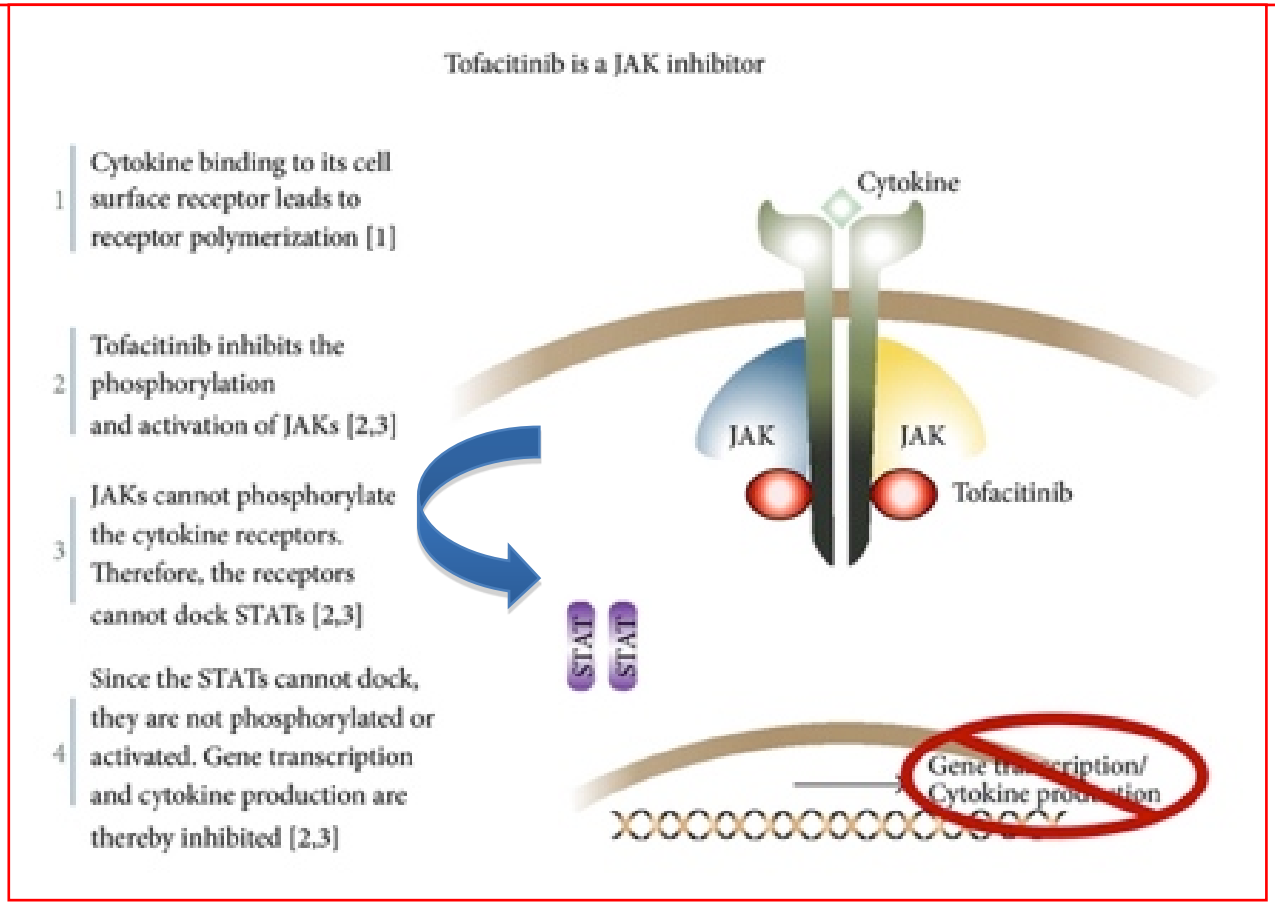

Tofacitinib: clinical trial (2016)

JCI Insight

CLINICAL MEDICINE

Safety and efficacy of the JAK inhibitor tofacitinib citrate in patients with alopecia areata

Milène Kennedy Crispin,[1] Justin M. Ko,[1] Brittany G. Craiglow,[2,3] Shufeng Li,[1] Gautam Shankar,[1] Jennifer R. Urban,[4] James C. Chen,[5,6] Jane E. Cerise,[5] Ali Jabbari,[5] Mårten C.G. Winge,[1] M. Peter Marinkovich,[1] Angela M. Christiano,[5,7] Anthony E. Oro,[1] and Brett A. King[2]

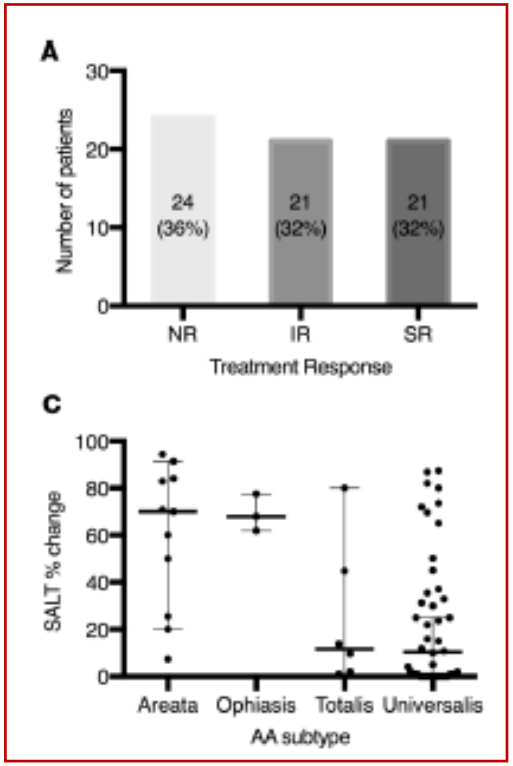

Kennedy Crispin M, Ko JM, Craiglow BG, Li S, Shankar G, Urban JR, Chen JC, Cerise JE, Jabbari A, Winge MC, Marinkovich MP, Christiano AM, Oro AE, King BA. Safety and efficacy of the JAK inhibitor tofacitinib citrate in patients with alopecia areata.

Anti-JAKs' updates

- A tofacitinib (inibitore JAK) è stata negata l'autorizzazione all'ingresso nel mercato da parte di CHMP nel 2013 per l'artrite reumatoide (RA), e successivamente accettata in seguito a revisione a marzo '16

- Efficacia superiore agli inibitori PDE4

- Tofacitinib sicurezza/ tollerabilità inferiori ad apremilast; si prevede sicurezza migliorata per i principi attivi della prossima generazione

- Anti-JAKs topici (inserire articolo)

Inserire nota bibliografica

Grazie per l'attenzione